

Peer reviewed article

Subcutaneous fat necrosis of the newborn¹

Sven Schulzke^a, Stanislaw Büchner^b,
Hubert Fahnenstich^b

^a Department of Neonatology, University Children's Hospital, Basel, Switzerland

^b Department of Dermatology, University Hospital, Basel, Switzerland

We report on a term girl born by urgent caesarean section due to variable foetal decelerations during labour. Weight 3830 g, Apgar scores 4/6/8 (1'/5'/10') and arterial umbilical cord pH 6.89. Suffering a mild respiratory distress syndrome for the first day of life with a maximum FiO₂ of 0.3, she was transferred to the neonatal intensive care unit. Transient arterial hypotension down to 29 mm Hg mean arterial pressure was rapidly corrected by two intravenous bolus administrations of 0.9% saline solution. Initially the capillary blood gases showed metabolic acidosis (pH 7.14, pCO₂ 30 mm Hg, BE -18 mmol/l), but recovered completely and spontaneously within 12 hours of life. No body surface cooling was applied. The neurological findings after 24 hours of life were normal and breastfeeding was started on day 2 without problems. Cranial ultrasound including doppler studies on day 2 revealed no signs of cerebral oedema or bleeding. The child was discharged to maternity in good health on day 5, but was readmitted on day 6 with obviously painful, firm, large erythematous nodules and plaques on her back, dorsal neck and upper arms (fig. 1). She was placed in the prone position and received paracetamol. Histological examination of a biopsy specimen from a nodule on her back revealed patchy fat necrosis with fat crystallisation. In addition, macrophages and foreign-body giant cells, neutrophils, lymphocytes and eosinophils were present in the inflammatory infiltrate (fig. 2). These findings were consistent with the diagnosis of subcutaneous fat necrosis of the newborn (SCFN). Additional diagnostic workup showed normal serum calcium levels of 2.2–2.6 mmol/l (1.3–1.6 mmol/l ionised calcium), no thrombocytopenia and no hyperlipidaemia. Starting on day 16, the cutaneous lesions gradually decreased in size and intensity, were less erythematous and no longer painful. The newborn was finally discharged home. At 12 weeks of age the cutaneous symptoms had resolved. She did not develop hypercalcaemia in the first year of life and neurological follow-up was excellent.

Discussion

SCFN involves painful, firm, erythematous nodules and plaques over the trunk,

arms, buttocks, thighs, and cheeks of full-term newborns. No epidemiological data are available for SCFN. Lesions appear in the first or second month of life and resolve within several weeks to months. A granulomatous infiltrate is formed subsequently. Lesions may calcify, and non-renal absorption of calcium increases. The exact pathophysiology of SCFN is unknown. Perinatal distress, as in asphyxia, meconium aspiration or hypothermia, followed by skin hypoperfusion, may lead to subcutaneous fat necrosis [1]. In the context of localised inflammation, mobilised calcium from the necrosis and elevated vitamin D levels, hypercalcaemia may occur [2]. Both the direct application of ice packs on the skin to treat supraventricular tachycardia and induced hypothermia in cardiac surgery are other factors which may lead to this condition [3, 4].

SCFN is a self-limiting disease but may be complicated by hyperlipidaemia, transient thrombocytopenia and, more commonly, severe hypercalcaemia [1]. Thrombocytopenia appears to occur concomitantly with the cutaneous symptoms and there are no reports of severe bleeding. Hypercalcaemia may occur after several weeks and result in seizures, blindness and even death due to infection or cardiac arrest [5, 6].

To be considered in differential diagnosis are sclerema neonatorum, histiocytosis and cellulitis; conditions such as erythema nodosum, lipogranulomatosis (Farber disease), neurofibroma or sarcoma should be ruled out. Diagnosis of SCFN usually requires a deep skin biopsy since it may be difficult to exclude sclerema neonatorum, which carries a mortality rate of 75% while the prognosis of SCFN is good [1, 7]. Histology shows patchy areas of fat necrosis surrounded by a granulomatous infiltrate of lymphocytes, macrophages and giant cells. Many of the fat and giant cells contain needle-shaped clefts often in a radial arrangement [8].

Treatment of SCFN consists of analgesia. If hypercalcaemia occurs it may require aggressive treatment. Empirical baseline treatment is fluid loading, termination of vitamin D substitution and a low calcium diet, together with diuretics such as furosemide to decrease oral calcium intake and increase renal calcium output [9]. If these measures do not maintain a normal calcium level, 1–2 mg/kg/d prednisone is used to control the granulomatous inflammatory process and lower vitamin D production [9]. Since hypercalcaemia may occur after several weeks and last for months, periodic checks on serum calcium are necessary in the first 3–6 months of life. Parents should be informed of the signs of hypercalcaemia such as failure to thrive, hypotonia and vomiting, and urged to contact their paediatrician if any should appear.

Newborn animal and small human pilot studies suggest that mild hypothermia following peripartum hypoxia-ischaemia in newborn infants may reduce neurological sequ-

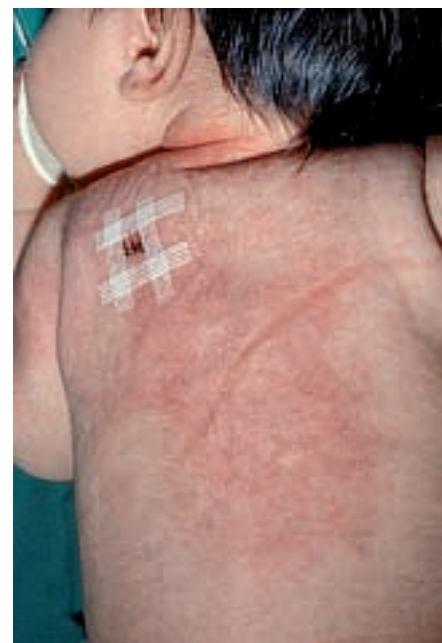

Figure 1

Rear view of an infant with subcutaneous fat necrosis showing large, firm, erythematous nodules and plaques over the back, neck and upper arms. Note the incision from a deep skin biopsy on the left shoulder.

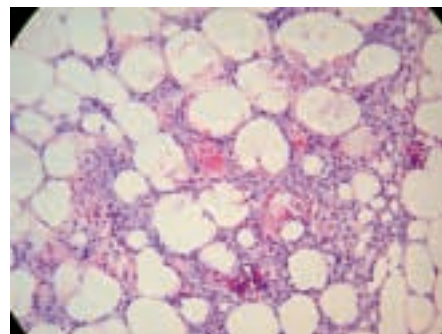


Figure 2

Histological slide of a biopsy nodule from the left shoulder showing patchy fat necrosis and crystallisation of fat (H&E, 40x).

lae [10]. However, as therapeutic hypothermia in asphyctic newborns results in a combination of two known risk factors for SCFN, cooling may increase the incidence of SCFN and lead to serious hypercalcaemia with a potentially deleterious outcome. The critical temperature and duration of hypothermia for development of SCFN are unknown. As far as we know, SCFN as an adverse outcome of induced hypothermia in birth asphyxia has been described in a single case report [1] but has not been addressed in trials investigating cooling for asphyxia [10]. We therefore suggest that SCFN be included as an adverse long term outcome measure of future trials on induced hypothermia for newborn infants with hypoxic ischaemic encephalopathy.

¹ This case was presented as an electronic case presentation on the website of the Swiss Society of Neonatology (www.neonet.ch)

*Correspondence:**Dr. Sven Schulzke**University Children's Hospital Basel**Roemergasse 8**CH-4005 Basel**sven.schulzke@unibas.ch***References**

- 1 Wiadrowski TP, Marshman G. Subcutaneous fat necrosis of the newborn following hypothermia and complicated by pain and hypercalcaemia. *Australas J Dermatol* 2001;42:207–210.
- 2 Hansen KN, Balslev T, Lyngbye TJ, Olesen B, Ebbesen F. Subcutaneous fat necrosis with hypercalcemia. *Ugeskr Laeger* 1995;157:5398–5399.
- 3 Craig JE, Scholz TA, Vanderhoof SL, Etheridge SP. Fat necrosis after ice application for supraventricular tachycardia termination. *J Pediatr* 1998;133:727.
- 4 Chuang SD, Chiu HC, Chang CC. Subcutaneous fat necrosis of the newborn complicating hypothermic cardiac surgery. *Br J Dermatol* 1995;132:805–810.
- 5 Fernandez-Lopez E, Garcia-Dorado J, de UP, Heras I, Santos-Borbujo J, Armijo M. Subcutaneous fat necrosis of the newborn and idiopathic hypercalcemia. *Dermatologica* 1990;180:250–254.
- 6 Hicks MJ, Levy ML, Alexander J, Flaitz CM. Subcutaneous fat necrosis of the newborn and hypercalcemia: case report and review of the literature. *Pediatr Dermatol* 1993;10:271–276.
- 7 Burden AD, Krafchik BR. Subcutaneous Fat Necrosis of the Newborn: a Review of 11 Cases. *Pediatr Dermatol* 1999;16:384–87.
- 8 Sharata H, Postellon DC, Hashimoto K. Subcutaneous fat necrosis, hypercalcemia, and prostaglandin E. *Pediatr Dermatol* 1995;12:43–47.
- 9 Dudink J, Walther FJ, Beekman RP. Subcutaneous fat necrosis of the newborn: hypercalcaemia with hepatic and atrial myocardial calcification. *Arch Dis Child Fetal Neonatal Ed* 2003;88:F343–345.
- 10 Jacobs S, Hunt R, Tarnow-Mordi W, Inder T, Davis P. Cooling for newborns with hypoxic ischaemic encephalopathy (Cochrane Review). *Cochrane Database Syst Rev* 2003(4): CD003311.

The many reasons why you should choose SMW to publish your research

What Swiss Medical Weekly has to offer:

- SMW's impact factor has been steadily rising, to the current 1.537
- Open access to the publication via the Internet, therefore wide audience and impact
- Rapid listing in Medline
- LinkOut-button from PubMed with link to the full text website <http://www.smw.ch> (direct link from each SMW record in PubMed)
- No-nonsense submission – you submit a single copy of your manuscript by e-mail attachment
- Peer review based on a broad spectrum of international academic referees
- Assistance of our professional statistician for every article with statistical analyses
- Fast peer review, by e-mail exchange with the referees
- Prompt decisions based on weekly conferences of the Editorial Board
- Prompt notification on the status of your manuscript by e-mail
- Professional English copy editing
- No page charges and attractive colour offprints at no extra cost

Editorial Board

Prof. Jean-Michel Dayer, Geneva
 Prof. Peter Gehr, Berne
 Prof. André P. Perruchoud, Basel
 Prof. Andreas Schaffner, Zurich
 (Editor in chief)
 Prof. Werner Straub, Berne
 Prof. Ludwig von Segesser, Lausanne

International Advisory Committee

Prof. K. E. Juhani Airaksinen, Turku, Finland
 Prof. Anthony Bayes de Luna, Barcelona, Spain
 Prof. Hubert E. Blum, Freiburg, Germany
 Prof. Walter E. Haefeli, Heidelberg, Germany
 Prof. Nino Kuenzli, Los Angeles, USA
 Prof. René Lutter, Amsterdam, The Netherlands
 Prof. Claude Martin, Marseille, France
 Prof. Josef Patsch, Innsbruck, Austria
 Prof. Luigi Tavazzi, Pavia, Italy

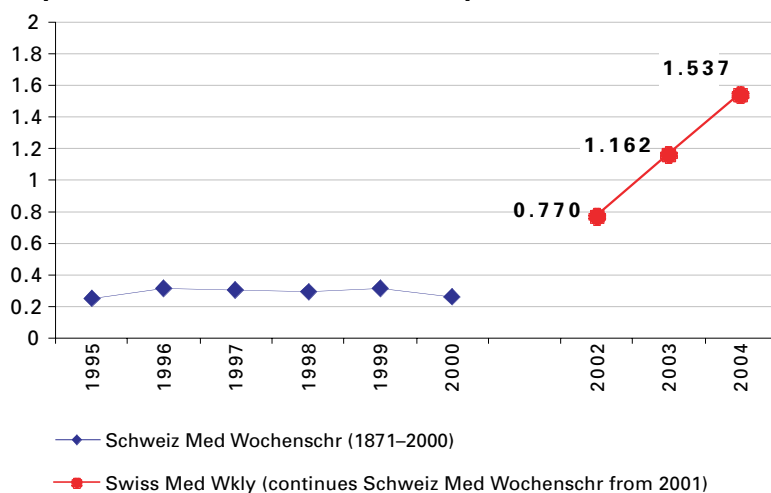
We evaluate manuscripts of broad clinical interest from all specialities, including experimental medicine and clinical investigation.

We look forward to receiving your paper!

Guidelines for authors:

http://www.smw.ch/set_authors.html

Impact factor Swiss Medical Weekly



All manuscripts should be sent in electronic form, to:

EMH Swiss Medical Publishers Ltd.
 SMW Editorial Secretariat
 Farnsburgerstrasse 8
 CH-4132 Muttenz

Manuscripts: submission@smw.ch
 Letters to the editor: letters@smw.ch
 Editorial Board: red@smw.ch
 Internet: <http://www.smw.ch>